

## PERIODONTICS



### Bipolar Versus Monopolar Electrosurgery: *Clinical Applications*

By Ian E. Shuman, DDS, FAGD

Traditional periodontal surgery has as its goal elimination of periodontal defects via resection or regeneration. While surgical entry in these cases relies upon a scalpel, other periodontal procedures can be approached by other means.

In all cases, however, certain technical goals are essential, including control of hemorrhage, visibility, absence of harmful effects to the surgical site and adjacent tissues, postoperative comfort, and rapid healing. One modality that has been used historically to accomplish certain periodontal surgical procedures is electrosurgery.

Conventional electrosurgery devices are monopolar, whereby tissue is cut by means of an advancing spark with the patient grounded and in the electrical loop. This modality has certain clinical disadvantages, including sparking, spread of the electrical current, and potential thermal damage to the tissues because of heat generation, which have limited its application.

Bipolar electrosurgery has recently been introduced for the treatment of oral and dental problems, with the goal of addressing certain problems associated with monopolar electrosurgery (Table). This article will discuss the mode of action of monopolar and bipolar electrosurgery, and present case reports illustrating the use of bipolar electrosurgery in clinical dentistry.

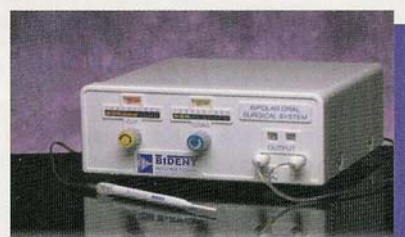

Figure 1. The Bident Bipolar Electrosurgery Instrument (Bident International) for dental use.

#### BACKGROUND

As first introduced, electrosurgery essentially "cooked" traumatized tissues from the outside inward. The cautery of human tissue was accomplished by application of red-hot metal rods and tips and/or boiling oil to the wound, which achieved hemostasis by forming a large tissue coagulum. Bleeding was controlled, allowing the mass of necrotic tissue to slough away. Advances in the last century have included the Spark Generator invented by Clark in 1910. This device released a powerful discharge and never achieved widespread acceptance.

In 1928, W. T. Bovie introduced an electrosurgical unit that functioned by means of a spark gap generator. The result was coagulation and cutting. More than 60 years ago, James Greenwood, using both sides of a standard Bovie generator, initiated the use of "two-point" coagulation, and demonstrated its superiority over monopolar coagulation.

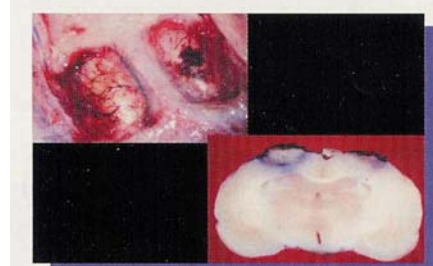

Figure 2. Gross specimen from rat brain study demonstrating the difference between monopolar and bipolar electrosurgery. The left side of the brain and the left side of the gross histological specimen are the result of a 3-second application of the minimal setting of monopolar electrosurgery (4Mhz) set to coagulate. Note the severity of damage to the site and the deeper tissues. The right side was treated with bipolar electrosurgery at its lowest setting (1Mhz) for 60 seconds of continuous coagulation. Note that only the major vessel was treated and that there was no current spread or heat dissemination to cause distant tissue damage.

Over the years, it has become customary to call the Bovie system "monopolar," whereas Greenwood's method is still referred to as "two point."

In 1955 Dr. Leonard Malis developed the first true bipolar coagulator using spark gap technology. The unit was marketed in 1966. In 1983 a totally solid state computer-controlled unit, the CMC II, was developed by Drs. Leonard and Jerry Malis. In 1999, a bipolar electrosurgery device specifically for use in dentistry was developed.

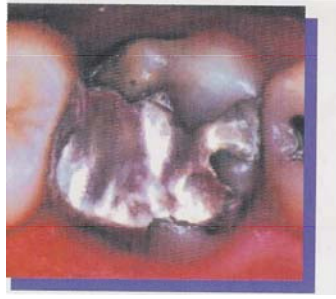

Figure 3. Tooth No.3 presented with a defective alloy, caries, an open margin, and tissue inflammation.

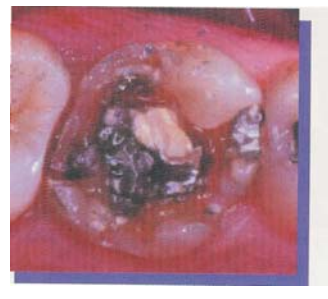

Figure 4. The tooth, following removal of almost all alloy, revealing base and caries

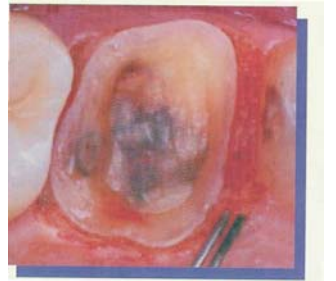

Figure 5. The bipolar 90" angled tip is used to remove inflamed interproximal and margin tissue

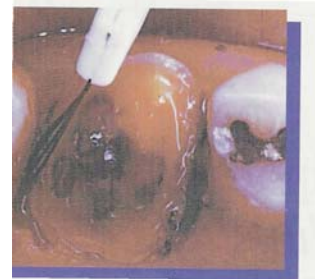

Figure 6. The narrow interproximal channel is easily negotiated with the bipolar tip to reduce edematous tissue and expose the margin.

It featured upgraded circuitry, finer control of the waveforms, and reduction in the size of the unit as appropriate for the dental operatory. The device, known as the Bident Bipolar Electrosurgery Unit (Bident International), is the only patented waveform bipolar electrosurgery unit that both cuts and coagulates (Figure 1). Therefore, in this article the Bident unit will be used to illustrate the dental aspects of bipolar electrosurgery that are discussed.

### MONOPOLAR AND BIPOLAR ELECTROSURGERY

The chief mode of action of monopolar electrosurgery is the cutting of tissue by means of an advancing spark, where the patient is grounded and in the electrical loop. This method causes sparking, current spread, and thermal damage in the tissues because of excessive generation of heat. This results in deleterious effects to the

tissue in proximity to the operative site.<sup>2</sup> In addition, when comparing monopolar electrosurgery and the scalpel incision, electrosurgery produces more tissue alteration and histological thermal artifacts as a result of the increased lateral heat produced by the low frequency radio wave of 0.5 to 2.9 MHz.<sup>3</sup> Therefore, the resultant effect of monopolar systems is excessive tissue damage and delayed healing. Microscopically, there is a denatured zone of collagen and connective tissue adjacent to the incision.<sup>4,5</sup> After 72 to 144 hours, subepithelial hematoma formation is observed in monopolar electrosurgical wounds. The bipolar electrosurgery device developed in 1983 was invented by a neurosurgeon for the purpose of addressing the inadequacies of monopolar electrosurgery when used in neurosurgery. Existing electrosurgery devices were unable to cut and coagulate soft tissues without harming adjacent tissues, and could not contact

hard tissue and foreign implant materials (ie, surgical screws and plates) without the potential for osteoradionecrosis.<sup>6,7</sup> In addition, monopolar electrosurgery was known to cause disruption of deeper blood vessels due to current spread and thermal damage. Furthermore, sparking from monopolar devices had the potential for causing explosions in the presence of oxygen and other highly flammable anesthetic gases. Bipolar electrosurgery was found to greatly reduce or eliminate these harmful effects. Animal studies<sup>3</sup> (Figure 2) were followed by human trials, and the unit was found to be both safe and effective. Because of its proven success, the bipolar electrosurgery device (Codman CMC II and the latest version, the CMC III; Valley Forge Scientific, distributed by Johnson and Johnson) are currently used in over 90% of the world's neurosurgical operating rooms.

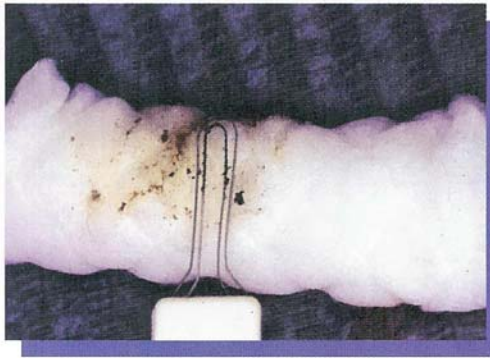


Figure 7. Tips are cleaned by simply wiping on a wet cotton roll (or 2x2 gauze) while activating the cut mode.

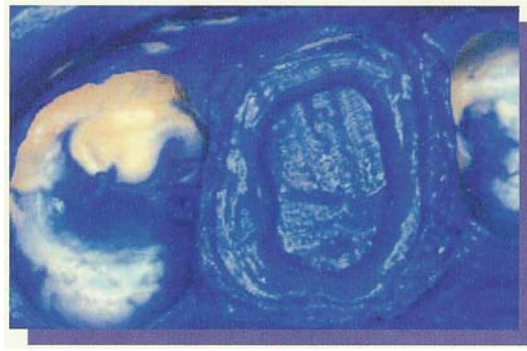


Figure 8. The final impression. Note the excellent intaglio, demonstrating the effectiveness of soft tissue removal.

These devices rapidly found a place in other disciplines, including general surgery, plastic surgery, and obstetrics and gynecology. In 1999, this technology was introduced to dentistry as a primary surgical instrument for treatment of various periodontal and oral surgical problems.

The cutting action of bipolar electro-surgery relies upon molecular resonance by a sine-wave cutting current that divides the tissue without causing sparking, thermal damage, or current spread<sup>1</sup>. In addition, the waveform parameters were established to achieve gentle, clean coagulation, and minimal charring, sticking, and vascular perforation. Unlike other generators that are ineffective when used with irrigation, the exceedingly low impedance of the bipolar device provides smooth and gentle coagulation in both wet and dry surgical fields. This unit may be used with a prolonged continuous application since it produces progressive coagulation rather than a single high-output discharge<sup>1</sup>.

Unlike monopolar electro-surgical units, the bipolar electro-surgical unit can be used with patients who have any type of medical device that can be adversely affected by radio waves, such as implanted pacemakers and defibrillators. The odor from the treated tissue is greatly eliminated because the surgical site can be used in a wet field, and its operation is actually improved in a damp-to-wet environment. In addition, irrigation can be used to flush the area of any

residual tissue remnants while hydrating the cut tissue ends, promoting improved healing.

Bipolar electro-surgery units utilize a handpiece with two closely approximated metal electrodes.<sup>9</sup> One electrode acts as the active broadcast electrode, and the other acts as the passive return electrode. In such a system, the radio frequency current flows from an active electrode, through a very discreet area of tissue, and immediately back into the adjacent passive electrode, completing the circuit to the power unit. This results in an extremely limited area of therapeutic action, and does not require current to be dissipated through the patient's general body tissues in order to reach the return electrode pad. Only the tissue between the two closely approximated electrode tips is part of the conduction pathway.

The following case studies represent examples of common periodontal and oral surgery cases in which bipolar electro-surgery was effectively used.

#### CASE REPORT 1: CIRCUMCORONAL GINGIVOPLASTY

One of the most common periodontal procedures performed by the restorative dentist is removal of circumcoronal tissue in order to capture an accurate marginal representation

in the final impression. To do so, the preparation's margins must be clear in the impression's intaglio. In this case, a large amalgam alloy restoration in a maxillary right first molar presented with proximal caries (Figure 3). In addition, an open mesial contact had resulted in inflammation of the interproximal soft tissues. Following removal of the restoration and caries (Figure 4), a decision was made to restore the tooth with an indirect onlay using a ceramic polymer, rather than a traditional PFM crown.

Following tooth preparation, the inflamed interproximal tissue was excised and the remaining circumcoronal tissue underwent gingivoplasty with an internal bevel. This promoted soft tissue health and allowed an accurate impression. Two different tips were used for this case: a 90° tapered wire (Figure 5) and a long narrow loop (Figure 6). During the procedure, cleaning the working tip is accomplished by wiping on a wet cotton roll or 2x2 gauze pad while the unit is activated in cut mode (Figure 7). It should be noted that at the distal margin contact was broken, and an extremely narrow access was made interproximally in order to maintain the conservative nature of the restoration. Accessing the narrow interproximal channel to remove the inflammatory tissue is a concern with monopolar electro-surgery, for fear of electrically shocking the patient because of inevitable tooth contact. However, with bipolar electro-surgery, and despite an extremely thin electrode tip, electrode-to-tooth contact may also be inevitable but is not a concern, as the unit can contact hard tissue (tooth and bone)

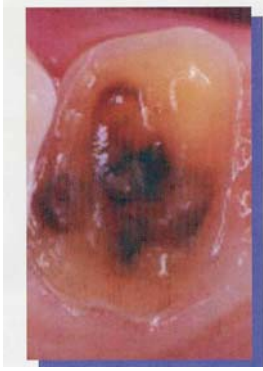

Figure 9. The tissue as it appeared 2 weeks post op. There is complete healing.

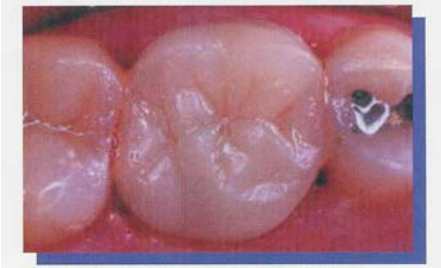


Figure 10. The final onlay restoration is bonded to the prepared tooth

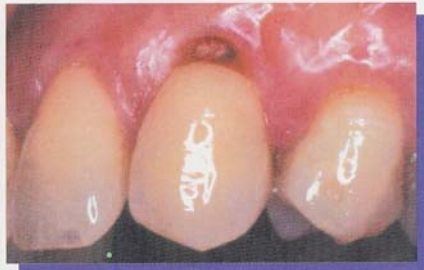

Figure 11. Tooth No.11 demonstrating caries that extends subgingivally.

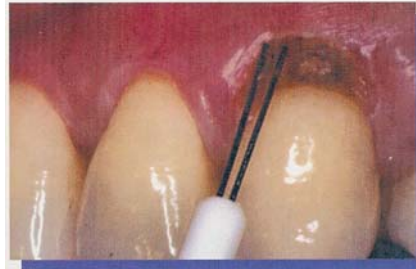

Figure 12. The tissue is excised using bipolar straight-wire tips

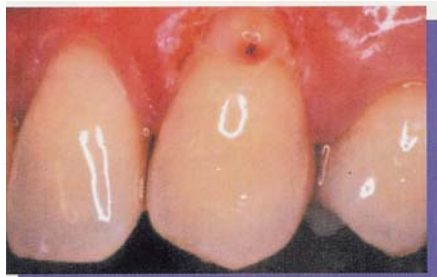

Figure 13. Tooth No.11 is now ready to accept a bonded restoration. The bipolar unit prevents bleeding and tissue fluids in the restorative site.

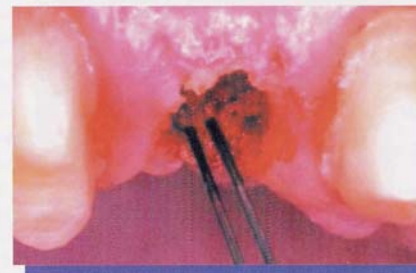


Figure 14. A buccal view of an implant exposed by removing the covering tissue circumferentially (Figures 14 through 16 courtesy of Dr. Henry Salama, Atlanta, Ga).

and foreign materials (restorations and implants) with complete safety. The result is definable margins in the final impression (Figure 8). Two weeks later, at insertion, the tissue was examined and appeared to be completely healed (Figure 9). The laboratory-fabricated onlay

(Figure 10) was cemented following standard protocols for resin bonding. The result was the restoration of the tooth without adverse effects on the surrounding structures.

#### **CASE REPORT 2: CARIES ACCESS AND EXPOSURE**

When subgingival caries is detected,

there are several factors that must be evaluated to determine the approach to exposure of sound tooth structure. Primary concerns are the amount of attached gingival tissue present and proximity to the alveolar crest. In this case, the maxillary right canine presented with a carious lesion that extended approximately

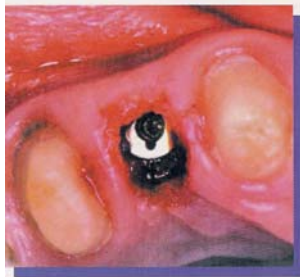

Figure 15. The occlusal view showing the exposed implant head

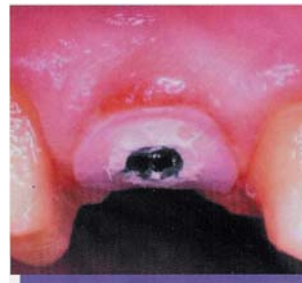

Figure 16. The implant with a healing abutment. Note the lack of bleeding and the tissue response. This method avoids scarring the facial tissue that may occur with traditional scalpel exposure.

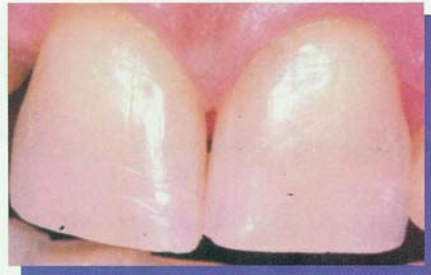

Figure 17. A preoperative view of the maxillary frenum. In this case, orthodontic treatment was complete, and a frenectomy was required (Figures 17 through 20 courtesy of Dr. Maurice Salama, Atlanta, Ga).

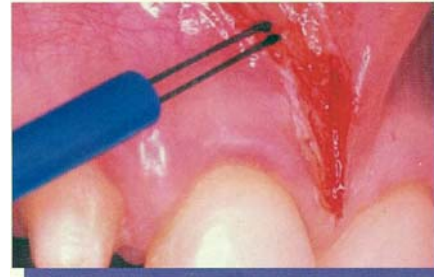

Figure 18. The right side was incised using bipolar electrosurgery with a straight-wire tip. Note the minimal amount of bleeding and complete absence of charred tissue.

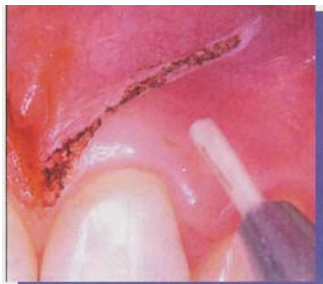

Figure 19. The left side was treated with a soft tissue laser. Charring is evident.

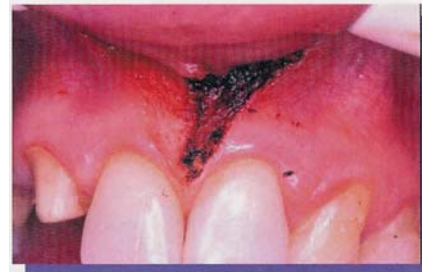

Figure 20. The completed frenectomy prior to suture placement. Note the obvious differences between the treatment modalities.

2 mm subgingivally (Figure 11). Because there was more than 6 mm of attached gingiva present, and the lesion was not proximate to bone, a gingivectomy was performed that exposed the remainder of the lesion and did not violate the biologic width. In order to create ideal contours, a thin straight wire was

selected for the bipolar electrosurgery unit (Figure 12). The caries was removed, and the tooth was prepared to receive a bonded restoration (Figure 13). Note that endodontic therapy was required in this case because of pulpal exposure. There was no gingival bleeding or tissue fluid present after the procedure,

which is essential prior to the placement of a bonded restoration.

### CASE REPORT 3: IMPLANT EXPOSURE

For implant exposure, the traditional approach has been elevation of a full-thickness mucoperiosteal flap. While this approach to access is

**Table. Features of Bipolar and Monopolar Electrosurgery Devices**

	BIPOLAR	MONOPOLAR
Ease of use	*	*
No heat dispersal <sup>1,2</sup>	*	
Clean surgical site	*	*
Hemorrhage control	*	*
Can be used in a wet field	*	
Atraumatic	*	
Cutting/coagulation controlled with a foot pedal	*	
No sparking of touched metal	*	
Coagulation necrosis <sup>6,7</sup>		*
Rapid post-op healing	*	
Minimal post-op discomfort	*	
Time required between cutting strokes <sup>10,11</sup>		*
No separate ground needed	*	

often required, it is no longer the only method for second stage surgery. In this case, an implant in the anterior maxilla was exposed by removal of a soft-tissue core coronal to the implant head (Figures 14 and 15). This was possible because the electrode tips can contact an implant without concern. Traditional monopolar electrodes cannot contact an implant because of the potential for electrical shock, osteoradionecrosis, and subsequent implant loss. However, when the bipolar electrode tips contact an implant, the Bident unit has a built-in safety feature that stops the electrical circuit. The implant was then restored (Figure 16).

**CASE REPORT 4: FRENECTOMY**

In this particular case, the patient had completed orthodontic treatment and required removal of the maxillary frenum (Figure 17). To compare two recognized approaches, the patient consented to having the left half of the frenum removed with a laser, and the right portion with bipolar electrosurgery. Following anesthesia, the site was moistened with water, and a bipolar straight-wire electrode was used to incise the right portion of the maxillary frenum (Figure 18). Following this, the left side was

then treated with the laser (Figure 19). The immediate result was charring of the tissue in the area treated with the laser (Figure 20). This was not seen in the area treated with bipolar electrosurgery (Figure 20).

**CONCLUSION**

The cutting action of bipolar electrosurgery is not based on vaporization or an advancing spark, but rather on molecular resonance, whereby the cutting current divides the tissue without sparking or charring. This system can operate in a wet or dry field, and thermal artifacts and charring are not observed. This article has discussed bipolar electrosurgery for different dental/oral applications. Further study of this promising modality for intraoral use is warranted.

**Acknowledgments**

The author thanks Drs. Ron Goldstein, Maurice Salama, and Henry Salama for their clinical expertise and assistance with the clinical cases. Also, thanks and gratitude to Dr. Jerry Malis and Mr. Matt Garfield for their expertise and guidance. Finally, thanks to Aesthetic Porcelain Studios Inc, Universal City, Calif, for their contribution to this article.

**References**

- 1 Dunn JD, Bipolar electrosurgery Dental Didactics: Health on the Net Foundation, p,3 wwwdental-didactics.com Accessed 12-01-00
- 2, Sherman JA, Principles and theory of radiosurgery, wwwellmancom, Accessed 12-04-00,
- 3 Malis LI New Trends in Microsurgery and Applied Technology In Pluchino F, Broggi G, eds Advanced Technology in Neurosurgery Berlin, Germany Springer-Verlag; 1988:1-16,
- 4 Kalkwarf KL, Krejci RF, Wentz FM Healing of electro-surgical incisions in gingival early histologic observations in adult men, *JPD* 1981;46:662-667
- 5 Kalkwarf KL, Krejci RF, Wentz FM, et al, Epithelial and connective tissue following electrosurgical incisions in human gingiva *J Oral Maxillof Surg* 1983;41:80-85
- 6 Noble WH, McClatchkey KD, Douglass GD A histological comparison of effects of electrosurgical resection using different electrodes, *JPD*, 1976;3:5:575-579
- 7 Gnanasekhar JD, Al-Duwairi YS Electrosurgery in dentistry *Quintessence Inti*, 1998;29:649-654
- 8, Simon BI, Schuback P, Deasy MJ, et al The destructive potential of electrosurgery on the periodontium *J Periodonto*, 1976;47:342-347
- 9 Dunn JD *Bipolar Electrosurgery*, wwwDental Didactics.com, 07-08-2001,

10 Kalkwarf KL, Krejci RF, Edison AR et al Lateral heat production, secondary to electrosurgical incision *Oral Surg*, 1983;55:344-348

11 Kalkwarf KL, Krejci RF, Edison AR Subjacent heat production during tissue excision with electrosurgery, *JOral Maxillofac Surg* 1983;41:653-657,

**Dr. Shuman** maintains a full-time private practice in Glen Burnie, Md emphasizing reconstructive and aesthetic dentistry.

He can be reached at (410) 766-5104 or [ishumands@erols.com](mailto:ishumands@erols.com),  
*Disclosure - Dr. Shuman has received research support from Bident International*